

Isolated nontraumatic abducens nerve palsy

Vesna V. Brinar¹, Mario Habek¹, David Ozretić², Višnja Djaković¹ and Vesna Matijević¹

¹Referral Center for Demyelinating Diseases of the Central Nervous System, University Department of Neurology ; ²Department of Radiology, Zagreb School of Medicine and University Hospital Center, Zagreb, Croatia

Abstract

Introduction : Abducens nerve palsy (ANP) is the most common isolated palsy. The injury of the abducens nerve can occur anywhere along its long course, so differential diagnosis of ANP occasionally demands thorough investigation to find the proper cause.

Patients : Ten patients with isolated ANP are presented. The causes included nasopharyngeal carcinoma, diabetes, cholesteatoma of the inner ear, carotid-cavernous fistula, subarachnoid bleeding, hydrocephalus, toxic ANP, multiple sclerosis, clinically isolated syndrome suggestive of multiple sclerosis, and Tolosa-Hunt syndrome.

Discussion : Based on the cases presented and review of the literature, we argue that every patient with isolated nontraumatic ANP requires brain MRI as an initial diagnostic tool. If this finding remains inconclusive, additional tests including angiography and CSF examination should be performed.

Key words : Abducens nerve ; palsy ; traumatic ; non-traumatic.

Introduction

Abducens nerve palsy (ANP) is the most common isolated palsy due to the long peripheral course of the nerve. The abducens nucleus is located in the caudal pons at the level of the facial colliculus. In the vicinity of the abducens nerve nucleus are facial nerve loop and pontine gaze center, so nuclear lesion of the abducens nerve is extremely rare. Abducens nerve exits the brainstem at the border of the pons and medullary pyramids. Upon exiting the brainstem it climbs superiorly along the ventral surface of the pons. On its way to the cavernous sinus it passes at the apex of the petrous portion of the temporal bone. In the cavernous sinus it passes medially to the internal carotid artery, and laterally to oculomotor, trochlear and 1st and 2nd branch of the trigeminal nerve to enter the orbit through the superior orbital fissure.

The injury of the abducens nerve can occur anywhere along this long course, so differential diagnosis of ANP occasionally demands thorough investigation to find the proper cause.

Because of its long course, abducens nerve is especially susceptible to traumatic injury, so for didactic reasons isolated ANP is divided into traumatic and nontraumatic. Isolated traumatic ANP, if partial, recovers in almost all patients, and if complete, in approximately 1/3 of the patients ; so if isolated, no other diagnostic work-up is necessary and treatment is conservative (1, 2). However, nontraumatic isolated ANP is a diagnostic challenge in daily routine and demands thorough investigation. The purpose of this article is to present ten cases of isolated nontraumatic ANP, to discuss differential diagnosis, and to suggest which neuroimaging and laboratory investigations are appropriate in which occasion.

PATIENT 1. A 44-year-old female patient presented to our emergency room because of dull headaches lasting for the past two months. Three weeks before she noticed double vision when looking to the right. Her past history was unremarkable. Neurological examination revealed right ANP, and the rest of cranial nerves, motor, sensory and coordination examination were normal. Emergency multi-slice computed tomography (MSCT) of the brain and neck revealed a large nasopharyngeal tumor spreading from the fossa pterygopalatina towards the oropharynx and cavernous sinus. The tumor was destroying the surrounding bone structures and the neck lymph nodes were enlarged in region 2 on the left side and region 5 on the right side. MSCT angiography was normal. Histopathologic examination of the biopsy specimen revealed it to be a case of non-differentiated non-keratinizing nasopharyngeal carcinoma. As the tumor was too large for surgery, radiotherapy was introduced.

PATIENT 2. A 74-year-old female patient was admitted to our Department because ten days before she had suddenly developed double vision when looking to the right. She denied any head trauma or other accompanying symptoms. Her past history revealed hypertension, peripheral facial nerve palsy 13 years before, intercostal herpes zoster 4 years before and acute pyelonephritis

3 years before. Neurological examination revealed right isolated ANP. Ultrasound and MSCT of the orbits were normal. Brain MRI revealed few chronic vascular lesions supratentorially, with normal brainstem. MR angiography was normal. Complete blood count and standard biochemistry tests were normal, except for elevated blood glucose level, with whole day profile ranging from 8.4 to 11.9 mmol/L. Cholesterol level was 6.5 mmol/L, and triglycerides 2.14 mmol/L. Definitive diagnosis was diabetic ANP. The patient was prescribed strict diabetic diet and repaglinide, however, the deficit persisted in spite of this therapy.

PATIENT 3. A 26-year-old female patient presented with a sudden onset of diplopia when looking to the right, accompanied by headache in the right temporal region. Three days before she had fever with cough and her general practitioner prescribed amoxicillin with clavulanic acid. During the next five days she presented to our emergency room for persistent double vision. Neurological examination on admission revealed isolated right ANP. Complete blood count, standard laboratory tests, thyroid hormones, cerebrospinal fluid (CSF) analysis, immunologic tests and anti-ganglioside antibodies (GM1, GM2, GD1a, GD1b, GQ1b) were negative. Brain MRI was normal, except for higher signal intensity on T2 and FLAIR sequences in both mastoids, consistent with chronic inflammation. MSCT of both pyramids revealed an expansive process localized in the posterior and lateral parts of the right mastoid, with destruction of mastoid cells. This diagnosis was confirmed upon mastoidectomy with exploration of the middle ear cavity, performed at ENT Department.

PATIENT 4. An 80-year-old female patient developed pain behind the left eye which woke her up from sleep. She noticed swelling of the left eyelids, redness of the sclera and double vision when looking to the left side. She also reported tinnitus in her left ear. She presented to the local emergency room. CT scan of the orbits revealed large tortuous veins in the medial eye angle, so a retrobulbar tumor process was suspected and she was referred to our Department for further evaluation.

On admission, she only complained of double vision when looking to the left side and straight. Her neurological examination revealed isolated left ANP. On auscultation of the left orbit, a high pitched bruit was audible, which disappeared upon compression of the ipsilateral carotid artery. Because of the suspicion of a carotid-cavernous fistula, digital subtraction angiography (DSA) was performed to confirm the diagnosis of carotid-cavernous fistula, Baraw type 1. She was treated with endovascular embolization. Control DSA was normal; however, ANP persisted on control visit at three months.

PATIENT 5. A 45-year-old patient developed diffuse, severe headache accompanied with double vision in all directions of gaze. Her past history was characterized by occasional pulsatile headaches on the left side, and serous meningitis at age 15. On admission, neurological examination revealed bilateral ANP. Emergency brain CT revealed signs of subarachnoid hemorrhage with intracerebral hemorrhage localized in the basal frontal lobe. Only in later stages the patient developed positive meningeal syndrome. MSCT angiography revealed a saccular aneurysm on the left pericallosal artery. Endovascular embolization of the aneurysm was performed but bilateral ANP persisted.

PATIENT 6. A 53-year-old male patient presented to our emergency room for headache, vomiting and double vision. On admission, neurological examination revealed left ANP. Cognitive, motor, sensory and coordination examination was normal. Emergency CT of the brain indicated hydrocephalus. The patient was scheduled for surgery, followed by complete recovery of ANP. The cause of hydrocephalus remained unresolved (normal control brain CT and normal CSF examination).

PATIENT 7. A 49-year-old female patient developed double vision when looking to the left side. Her symptoms worsened in the evening. Her past medical history was unremarkable; she had no hypertension or diabetes. Neurological examination revealed isolated left ANP. Brain MRI was normal. CSF examination, immunologic tests and thyroid function tests were normal. Prostigmine test was negative. A trial of corticosteroid therapy was initiated but with no response. The patient was discharged as isolated sixth nerve palsy of unknown etiology. During the next three months her symptoms progressed, so she had double vision even when looking straight. Control laboratory examination was normal. This time DSA was performed to yield normal result. Six months later her neurological examination remained the same. The patient was working in graphic industry with aniline dyes. She had a habit of licking her fingers while dying. Although not proven, the presumptive etiology of her sixth nerve palsy was aniline dye toxicity.

PATIENT 8. A 35-year-old female patient presented with double vision when looking to the right side. Neurological examination revealed right ANP. Her past medical history revealed paresthesia of the left extremities two years before; however, at that time she did not seek medical attention and spontaneous recovery ensued. She did not suffer from diabetes, hypertension, or any other chronic illness. Brain MRI showed many hyperintense lesions in T2 and FLAIR sequences, located periventricularly and subcortically as well as in the pons, medulla

and both cerebellar hemispheres. After gadolinium administration, post-contrast enhancement of the pontine lesion was seen. Immunologic tests were normal; visual evoked potentials (VEP) showed prolonged latencies. CSF examination revealed pleocytosis of 71 lymphocytes, elevated CSF protein level (0.54 g/L; normal value 0.17-0.37 g/L), and intrathecal synthesis of IgG oligoclonal bands (OCB). The diagnosis of relapsing remitting multiple sclerosis (MS) was made, and treatment with intravenous methylprednisolone was initiated, with complete recovery of ANP.

PATIENT 9. A 19-year-old male patient presented with a two-week history of diplopia when looking to the right side. Neurological examination revealed isolated right ANP. His previous history was unremarkable. Brain MRI showed multiple periventricular white matter hyperintensities as well as one hyperintense lesion on the right side of the pons (Fig. 1a and b). CSF examination revealed 147 lymphocytes and OCBs were positive. VEP were normal. Pulsed corticosteroid therapy was initiated, with almost complete recovery of ANP. The patient was diagnosed with a clinically isolated syndrome suggestive of MS.

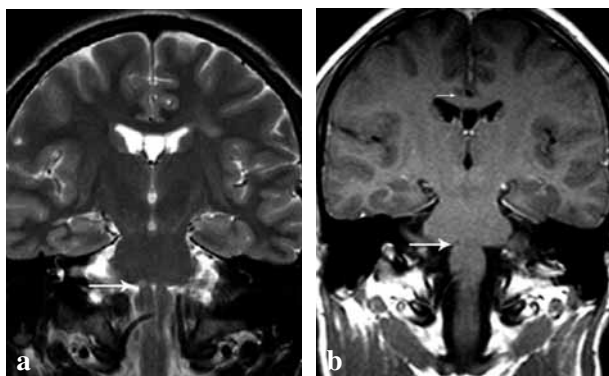


FIG. 1. — Patient 9, brain MRI: (a) T2 weighted sequences showing multiple white matter hyperintensities, one of which is located in the pons on the right side, responsible for the symptoms (arrow); (b) T1 weighted sequence after gadolinium enhancement showing that the pontine lesion is hypointense, with no post-contrast enhancement (arrow).

PATIENT 10. A 23-year-old male patient presented with a 10-day history of pulsate headache which he localized behind the left eye. Three days before admission he had noticed double vision when looking to the left side. Neurological examination revealed isolated left ANP. Brain MRI revealed an isointense lesion in the left cavernous sinus with post-gadolinium enhancement. Tolosa-Hunt syndrome was suspected and corticosteroid therapy was introduced. Despite therapy there was no improvement of ANP and one month later repeat brain MRI showed an even larger (20 mm) isointense lesion in the left cavernous sinus with post-

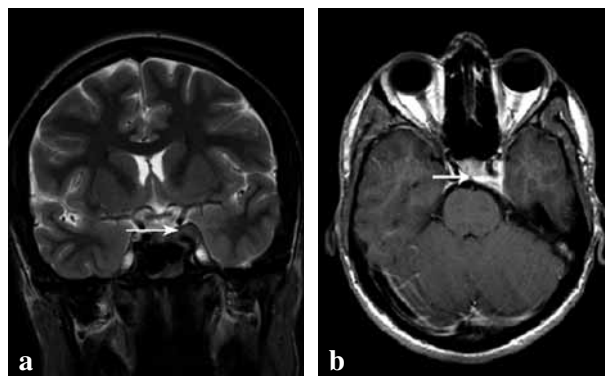


FIG. 2. — Patient 10, brain MRI: (a) coronal T2 weighted sequence showing isointense lesion in the left cavernous sinus (arrow); (b) the lesion shows strong enhancement after gadolinium enhancement on T1 weighted sequences, transverse section (arrow).

gadolinium enhancement (Fig. 2a and b). All other standard laboratory parameters, immunologic tests, anti-ganglioside antibodies, ACE and CFS examination were normal. Corticosteroid treatment was introduced again and the patient was scheduled for surgery two weeks later. However, this time corticosteroid therapy led to improvement of ANP and no pathologic substrate was intraoperatively found in the left cavernous sinus. Control MRI obtained 5 months later was normal and the diagnosis of Tolosa-Hunt syndrome was confirmed.

Discussion

The incidence of ANP is 11.3/10000, with a peak in the seventh decade of life (3). In this population based study, the most frequent cause was hypertension alone (19%), coexistent hypertension and diabetes (12%), trauma (12%), multiple sclerosis (7%), neoplasm (5%), diabetes alone (4%), stroke (4%), post-neurosurgery (3%), aneurysm (2%) and other 8%. However, according to data from this study, 34% of cases remain unsolved. Based on these data, the authors suggest that patients with isolated non-traumatic ANP, in which neurological examination and thorough history argue otherwise, do not need extensive work-up, i.e. neuroimaging and CSF examination, and advocate monthly follow up. However, the main drawback of the study is that MRI was performed in only six of 32 undetermined cases, thus the possibility of missing the underlying pathology being very high.

On the other hand, in tertiary, referral-based studies a much higher incidence of more serious pathology was found. These studies have shown that according to causes, patients can be divided into three age groups: (a) children – where most causes are either postviral or tumor and trauma (4); (b) young adults aged 20-50 – where the pathology is most difficult to predict (5); and (c) patients

older than 50 where microvascular disease is the most frequent cause (6). In the middle age groups, causes like CNS mass lesion, MS, postviral, idiopathic intracranial hypertension, meningitis, and neurodegenerative diseases should be suspected and appropriate diagnostic tests taken (5). Important conclusion from the study by Peters *et al.* is that ANP, even when isolated, harbors serious pathology like MS or CNS mass lesion in a significant percentage of patients, thus arguing for brain imaging for every ANP. In the only prospective study that evaluated the role of MRI in 43 consecutive isolated ANP patients, the authors found serious pathology in 63% of cases (7).

When approaching a patient with isolated ANP, the first question should be where the lesion is and are there any history data that could point to the right direction. Pontine lesions rarely cause isolated ANP because all pontine pathways and nuclei are located very near each other. Because of this, isolated nuclear lesion of the abducens nerve is virtually impossible. All of the published cases of isolated pontine ANP were caused by a lesion of the abducens nerve fascicule, and MS is the most frequent cause. ANP is a presenting sign in 0.5% of all MS patients, and MS is the cause in 0.8% of all sixth nerve palsy cases (8). Our patients No. 8 and No. 9 are two more examples of fascicular pontine ANP. The rest of neurological examination was completely normal and there were no other signs or symptoms that would suggest MS, and it was only on brain MRI that the true nature of the disease was discovered. Other possible causes of isolated pontine ANP are stroke or tumors, but are extremely rare (9-11).

The next site of the possible abducens nerve injury is on its course through Dorello's canal under the petroclinoid ligament. The classic triad of purulent otorrhea, deep facial pain and sixth nerve palsy is called Gradenigo syndrome. However, the full blown clinical presentation is rarely encountered, and the diagnosis of Gradenigo syndrome is often delayed (12). Although sixth nerve palsy is the least frequent sign, one isolated case has been described (13). Our patient No. 3 had isolated sixth nerve palsy accompanied by nonspecific pain in the right temporal region. The diagnosis of Gradenigo syndrome was made because of the appropriate use of neuroimaging. Other possible but rare causes of abducens nerve palsy at the petrous apex are sinus venous thrombosis and petrous meningiomas (14, 15).

ANP as a consequence of cavernous sinus pathology is well known and diseases like Tolosa-Hunt syndrome (16), carotid-cavernous fistula (17), or tumor (18) are the most likely causes. If ANP in such instances is isolated as in our patients No. 4 and No. 10, symptoms like headache or tinnitus should prompt emergency neuroradiological investigation.

ANP occurs in approximately 10% of all patients with nasopharyngeal carcinoma (19). However, ANP as an isolated symptom of nasopharyngeal carcinoma is much rarer (20). Again in patient No. 1 pain was the only accompanying symptom that prompted us to do MSCT.

Isolated bilateral ANP is rare and the most frequent causes are aneurysms and subsequent subarachnoid hemorrhage, cardiovascular-related cerebrovascular accident, and arteriovenous malformations, tumors, encephalitis, vasculitis, and meningitis (21). However, all these causes have the same underlying mechanism, i.e. raised intracranial pressure, which can also be the cause of isolated unilateral ANP, as we have shown in patients No. 5 and No. 6. In some rare instances, myasthenia, orbital muscle entrapment, convergence spasm, divergence palsy, and pretectal pseudoconvergence should be considered, but these diagnoses are usually not difficult to make (22).

Despite many causes, a great proportion of ANP cases remain unsolved, but toxicity should be investigated in great detail. Our patient No. 7 developed persistent isolated ANP, which did not resolve after three years of follow up and repeat MRI did not reveal the cause. Although never proven, the only etiologic factor was aniline dye toxicity.

There are many disagreements about evaluation of patients with ANP in the literature. Because hypertension and diabetes cause ANP in up to 35% of patients, some authors argue that monthly follow up is the best approach (3). The main disadvantage of these studies is lack of brain MRI, which is not performed in all patients. On the other hand, prospective studies have shown serious pathology in 63% of ANP patients (7), with even higher percentage in patients younger than 50 years. Although we presented a small series of selected patients and there is a selection bias, we argue that every patient with isolated nontraumatic ANP requires brain MRI as a first line investigation. If the brain MRI reveals underlying pathology, appropriate treatment can be started, in which case these patients have much better outcome.

Conclusion

Based on the cases presented and review of the literature, we argue that every patient with isolated nontraumatic ANP requires brain MRI as an initial diagnostic tool. If this finding remains inconclusive, additional tests (angiography and CSF examination) should be performed.

REFERENCES

- HOLMES J. M., BECK R. W., KIP K. E. *et al.* Predictors of nonrecovery in acute traumatic sixth nerve palsy and paresis. *Ophthalmology*, 2001, **108**: 1457-60.

2. HOLMES J. M., DROSTE P. J., BECK R. W. The natural history of acute traumatic sixth nerve palsy or paresis. *J. AAPOS*, 1998, **2** : 265-8.
3. PATEL S. V., MUTYALA S., LESKE D. A. *et al.* Incidence, associations, and evaluation of sixth nerve palsy using a population-based method. *Ophthalmology*, 2004, **111** : 369-75.
4. LEE M. S., GALETTA S. L., VOLPE N. J. *et al.* Sixth nerve palsies in children. *Pediatr. Neurol.*, 1999, **20** : 49-52.
5. PETERS G. B. 3rd, BAKRI S. J., KROHEL G. B. Cause and prognosis of nontraumatic sixth nerve palsies in young adults. *Ophthalmology*, 2002, **109** : 1925-8.
6. RICHARDS B. W., JONES F. R. Jr, YOUNGE B. R. Causes and prognosis in 4,278 cases of paralysis of the oculomotor, trochlear, and abducens cranial nerves. *Am. J. Ophthalmol.*, 1992, **113** : 489-96.
7. BENDSZUS M., BECK A., KOLTZENBURG M., VINCE G. H. *et al.* MRI in isolated sixth nerve palsies. *Neuroradiology*, 2001, **43** : 742-5.
8. BARR D., KUPERSMITH M. J., TURBIN R. *et al.* Isolated sixth nerve palsy : an uncommon presenting sign of multiple sclerosis. *J. Neurol.*, 2000, **247** : 701-4.
9. PAIK J. W., KANG S. Y., SOHN Y. H. Isolated abducens nerve palsy due to anterolateral pontine infarction. *Eur. Neurol.*, 2004, **52** : 254-6.
10. ATILLA H., ISIKAY C. T., KANSU T. Isolated sixth nerve palsy from pontine infarct. *Acta Neurol. Belg.*, 2000, **100** : 246-7.
11. MAK W., CHEUNG R. T., FAN Y. W. *et al.* Metastatic adenocarcinoma masquerading as basal pontine tuberculoma. *Clin. Neurol. Neurosurg.*, 1999, **101** : 111-3.
12. CHOLE R. A., DONALD P. J. Petrous apicitis. Clinical considerations. *Ann. Otol. Rhinol. Laryngol.*, 1983, **92** : 544-51.
13. PRICE T., FAYAD G. Abducens nerve palsy as the sole presenting symptom of petrous apicitis. *J. Laryngol. Otol.*, 2002, **116** : 726-9.
14. MARZO S. J. Sigmoid sinus thrombosis with contralateral abducens palsy : first report of a case. *Ear Nose Throat J.*, 2001, **80** : 869-70.
15. KAWASE T., SHIOBARA R., OHIRA T. *et al.* Developmental patterns and characteristic symptoms of petroclival meningiomas. *Neurol. Med. Chir. (Tokyo)*, 1996, **36** : 1-6.
16. ALIOGLU Z., AKBAS A., SARI A. *et al.* Tolosa Hunt syndrome : a case report. Clinical and magnetic resonance imaging findings. *J. Neuroradiol.*, 1999, **26** : 68-72.
17. IWASAKI M., MURAKAMI K., TOMITA T. *et al.* Cavernous sinus dural arteriovenous fistula complicated by pontine venous congestion. A case report. *Surg. Neurol.*, 2006, **65** : 516-8.
18. MALLOY K. A. Prostate cancer metastasis to clivus causing cranial nerve VI palsy. *Optometry*, 2007, **78** : 55-62.
19. ILHAN O., SENER E. C., OZYAR E. Outcome of abducens nerve paralysis in patients with nasopharyngeal carcinoma. *Eur. J. Ophthalmol.*, 2002, **12** : 55-9.
20. CHAN J. W. Sixth nerve palsy in nasopharyngeal carcinoma. *Neurology*, 2003, **61** : 1417.
21. DURKIN S. R., TENNEKON S., KLEINSCHMIDT A. *et al.* Bilateral sixth nerve palsy. *Ophthalmology*, 2006, **113** : 2108-9.
22. KEANE J. R. Bilateral sixth nerve palsy. Analysis of 125 cases. *Arch. Neurol.*, 1976, **33** : 681-3.

Mario HABEK, M.D.,
 University Department of Neurology,
 Zagreb University Hospital Center,
 Kišpatićeva 12,
 HR-10000 Zagreb (Croatia).
 E-mail : mhabe@mef.hr